



## Histological and Histochemical Observations on Gizzard of Parent Stock of Vanaraja

**Nirbhay Kumar Singh, Manoj Kumar Sinha and Avnish Kumar Gautam**

*Department of Veterinary Anatomy, Bihar Veterinary College Patna-800014*

### Abstract

The present study was designed to study certain histological and histochemical characteristics of gizzard in parent stock of Vanaraja by light microscope. The study was conducted on twelve adult Vanaraja birds of either sex whose weight varied from 1.5–2 Kg. All the birds were purchased from Central poultry farm Bihar Animal Sciences University, Patna. Before culling the birds were anaesthetised by giving inhalant anaesthesia and the organs were immediately removed after slaughter. The organs were gently cleaned and fixed in 10% buffered neutral formalin and then processed for various histological and histochemical studies. The histological observations revealed that like other species of birds the Gizzard of Vanaraja consisted of four tunics; tunica mucosa, tunica submucosa, tunica muscularis and tunica serosa. The mucosa of gizzard was lined with thick layer of cuticle which consisted of gastric pits. The lamina epithelialis was lined with simple cuboidal epithelium and the lamina propria contained simple tubular glands which were arranged in groups and these glands were lined by simple cuboidal epithelium. The secretion of inner part of the tubular glands was eosinophilic in nature. PAS positive substances were distributed nearly in almost entire region. It was scattered within the lumen of the glands, within the cells lining the surface and crypts. It was also observed within the deep glandular cells. The submucosa consisted of connective tissue formed mainly of collagen fibers. The tunica muscularis was very thick formed from parallel bundles of smooth muscle fibers which were separated by thin layer of connective tissue. The tunica serosa was made up of connective tissue which was covered with mesothelium.

**Key words :** Gizzard, histology, vanaraja, chicken.

### Introduction

A major contribution to India's economy is contributed by livestock and poultry sector (1). Out of total income earned by Agriculture sector 17% is contributed by the poultry sector. Poultry are mainly reared for their egg and meat which have high quality nutrients and micronutrients which are essential for a balanced diet. Vanaraja chicken breed is a dual purpose multicolored breed mainly reared for its egg and meat production. The breed was developed for its high juvenile body weight, better feed conversion ratio, better immunity and an ideal body weight of about 1.5-2 Kg at the time of sexual maturity. Backyard poultry farming of Vanaraja is gaining great economic importance in agribusiness. They can be reared in rural village conditions with minimum input and low cost of production than those produced under intensive rearing condition with high input cost. Gizzard play a significant role as the performance of a bird depends on its digestive system and the feed which subsequently affect the F.C.R which is required for growth, maintenance, and egg production. Although (2) studied certain morphological, histological and histochemical structures on gizzard of Uttara fowl but very few literature is available on the gizzard of Vanaraja. Hence the present study was undertaken to reveal the microscopic structure of gizzard of Vanaraja chicken.

### Materials and Methods

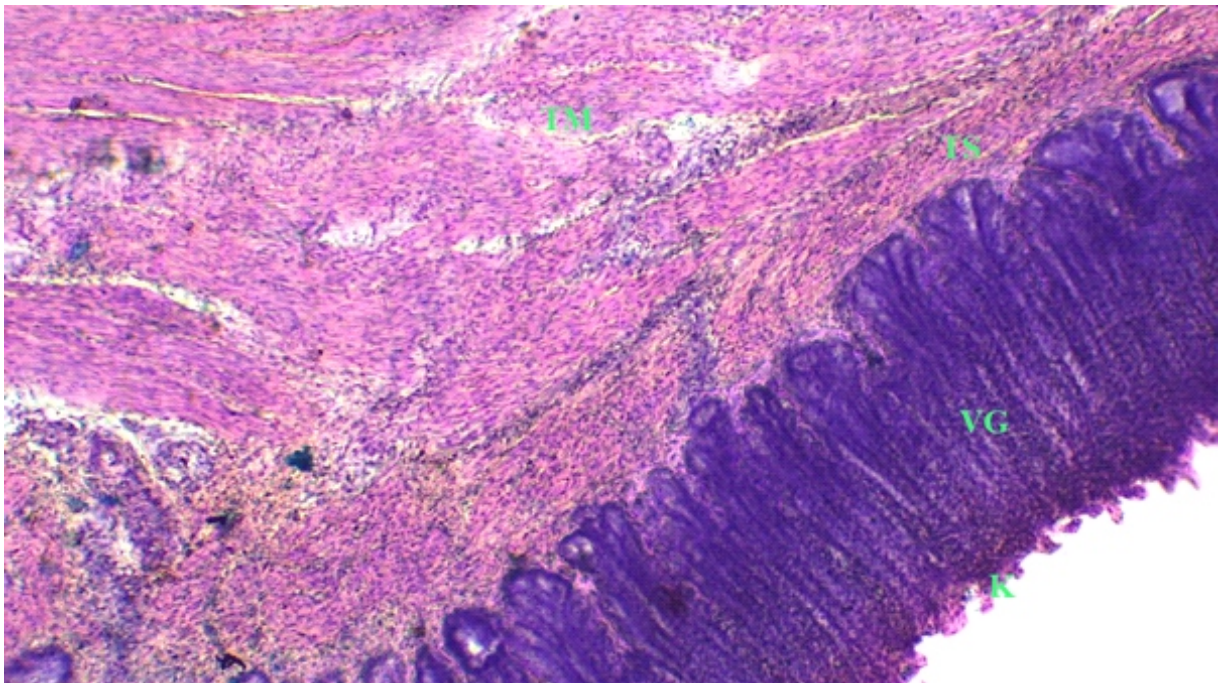
The present study was conducted on twelve adult

Vanaraja birds of either sex whose weight varied from 1.5–2 Kg. All the birds were purchased from Central poultry farm Bihar Animal Sciences University, Patna. Before culling the birds were anaesthetised by giving inhalant anaesthesia and the organ was collected and preserved in 10% neutral buffered formalin for histological and histochemical studies. After fixation a tissue of 5 mm thickness was cut with the help of BP blade and processed for various histological and histochemical processes such as washing, dehydration, clearing, paraffin impregnation, embedding and sectioning. Paraffin sections were cut at 5-7 micron thickness with the help of semiautomatic rotary microtome and sections were stained with different staining procedures for various microscopic observations as per (3).

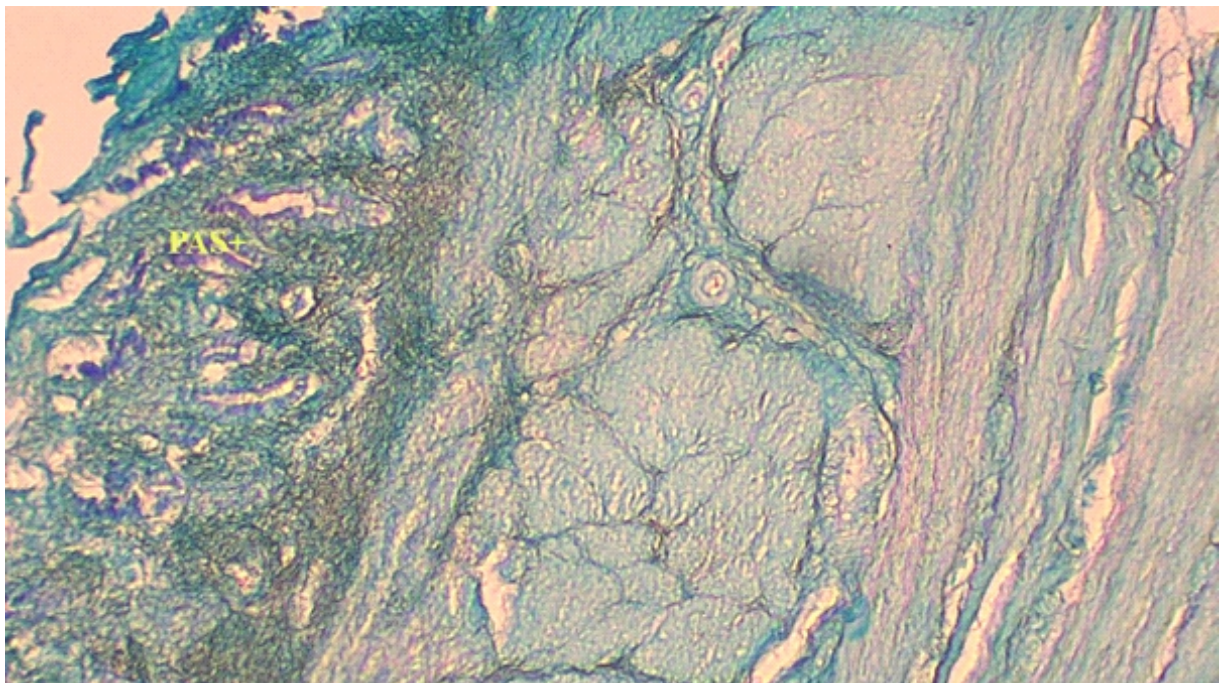
### Results and Discussion

The wall of gizzard of parent stock of Vanaraja consisted of four tunics: tunica mucosa, tunica submucosa, tunica muscularis and tunica serosa (fig.-1). The observations were in consistent with the findings of (4) in fowl, (5) in gizzard of yellow-billed grossbeak, (6) in fowl, (7) in proventriculus and gizzard of Japanese quail, (8) in fowl. In addition to the four layers, an internal secretory lining layer called koilin was found above the mucosa which was in accordance with the findings of (9) in Guinea fowl.

The tunica mucosa consisted of lamina epithelialis and lamina propria. The lamina muscularis mucosae was not observed (Fig.-2). This finding was relevant with the



**Fig.-1 :** Photomicrograph of transverse section of gizzard of parent stock of Vanaraja showing koilin layer(K), ventricular glands (VG), tunica submucosa (TS) and tunica muscularis (TM). H & E stain, X100.

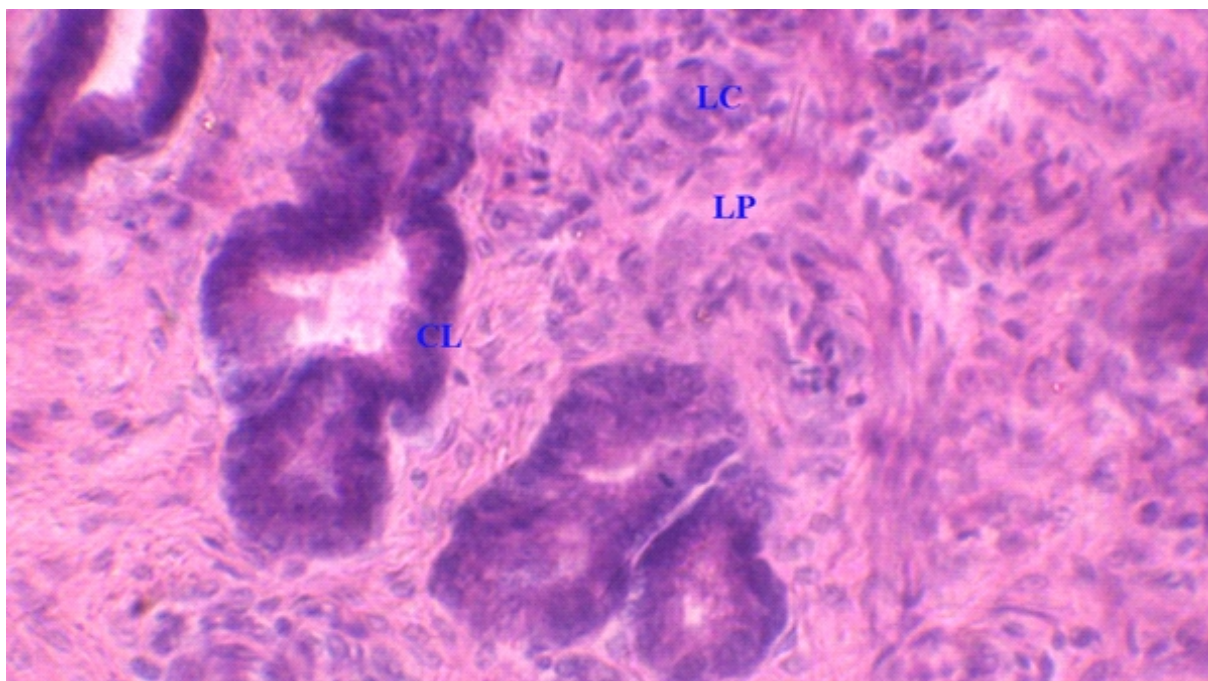


**Fig.-2 :** Photomicrograph of transverse section of gizzard of parent stock of Vanaraja showing ventricular glands (VG), tunica submucosa (TS), inner muscular layer (IML) and outer muscular layer (OML). H & E stain, X100.

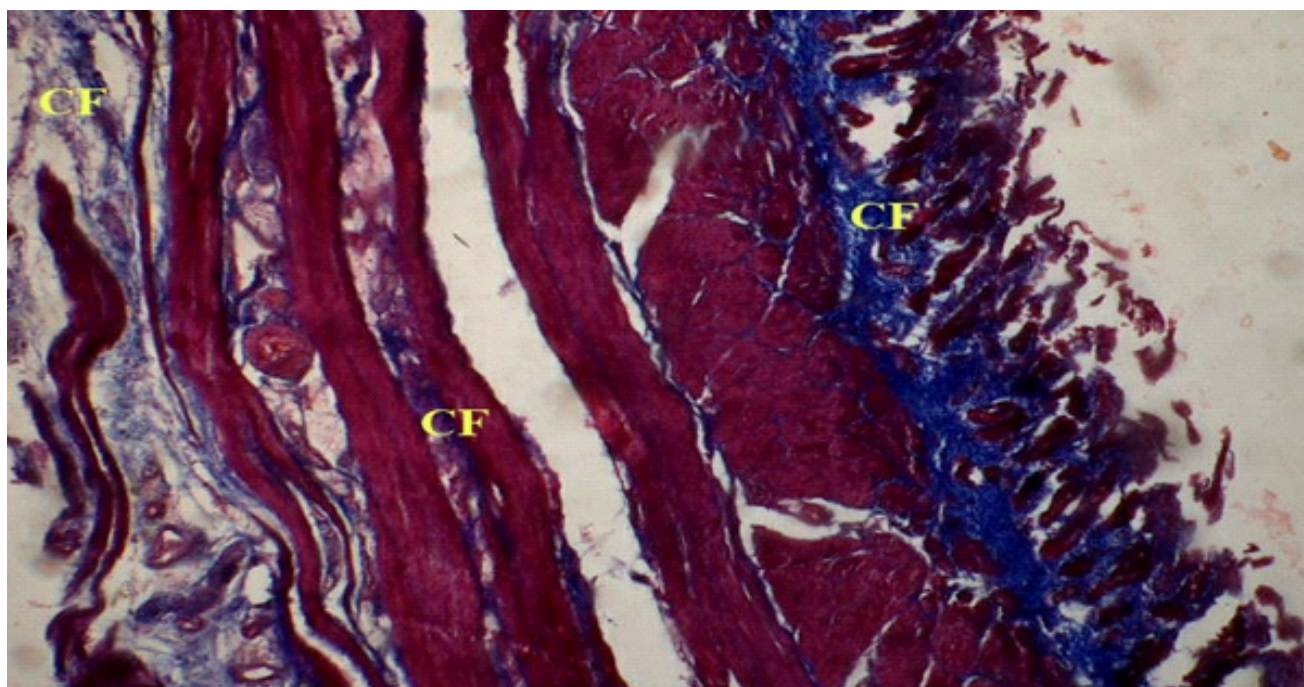
observations of (10) in blue and yellow Macaws and (11) in the gizzard of red-capped cardinal and chicken in which they reported that tunica mucosa was absent. Upon the surface of tunica mucosa there was a thick layer of cuticle that may be detached throughout the preparation of histological section.

The mucosa consisted of gastric pits. The lamina

epithelialis was lined with simple cuboidal epithelium and was invaginated towards the lamina propria. The present observations were similar to the observations made by (12) in Mallard and (13) in Coot bird (*Fulica atra*). Lamina propria consisted of simple tubular glands that produced a material called the gastric cuticle mucosa as mentioned by (14). The pits extended along the glandular layer



**Fig.-3 : Photomicrograph of transverse section of gizzard of parent stock of Vanaraja showing thick koilin layer (K) and ventricular gland (VG) H & E stain, X100.**



**Fig.-4 : Photomicrograph of transverse section of gizzard of parent stock of Vanaraja showing ventricular glands (VG) lined with cuboidal cells (CC). H & E stain, X400.**

(fig.-3). The finding was in agreement with the previous results of (15) who mentioned that the lamina propria is rather obscured by the glandular tubules which penetrate down through its thickness and terminate at the level of the submucosa. These glands are lined by simple cuboidal epithelium. The inner part of these tubular glands consisted of an eosinophilic secretion along with the

cuticle (fig.-4). This observation was similar to the findings of (16) who mentioned that the lamina propria composed of loose connective tissue and consisted of blood vessels, lymphatic vessels, nerve, and glands.

The cuticle showed a positive reaction to PAS stain. The reaction with PAS positive material distributed nearly in almost entire region. It was within the lumen of the

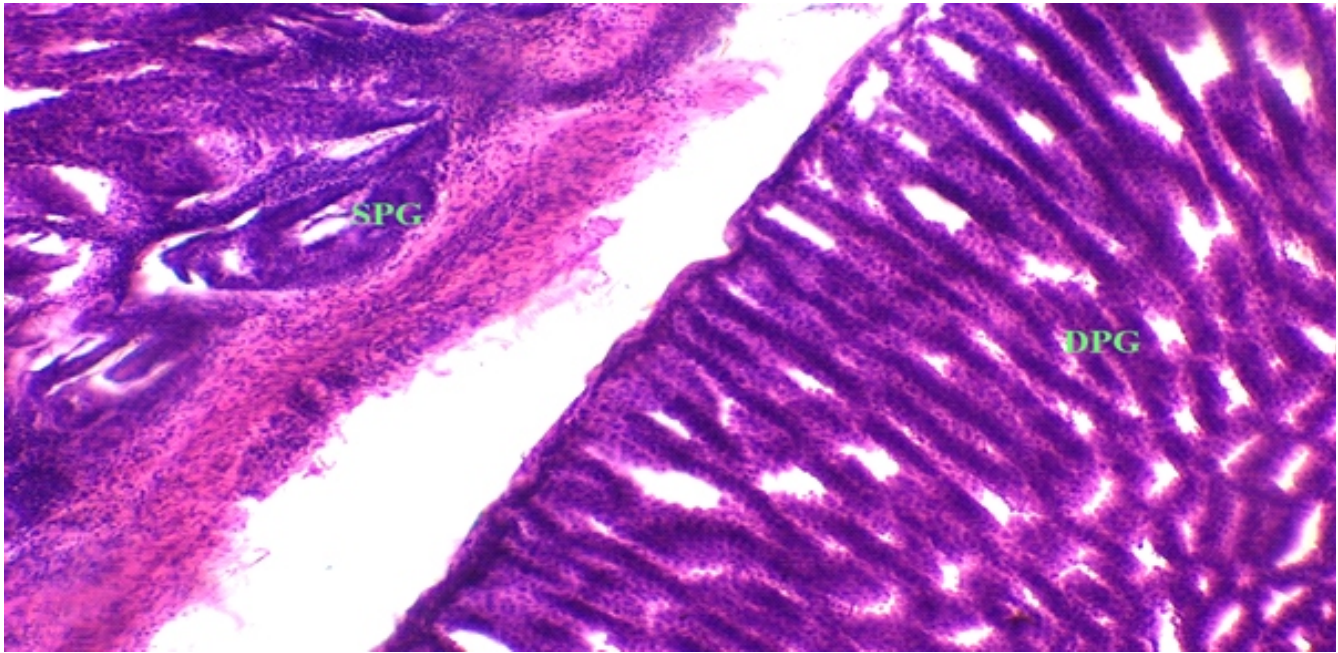


Fig.-5 : Photomicrograph of transverse section of gizzard of parent stock of Vanaraja showing PAS positive koilin layer and tubular glands in the region of laminae propria, PAS stain, X100.

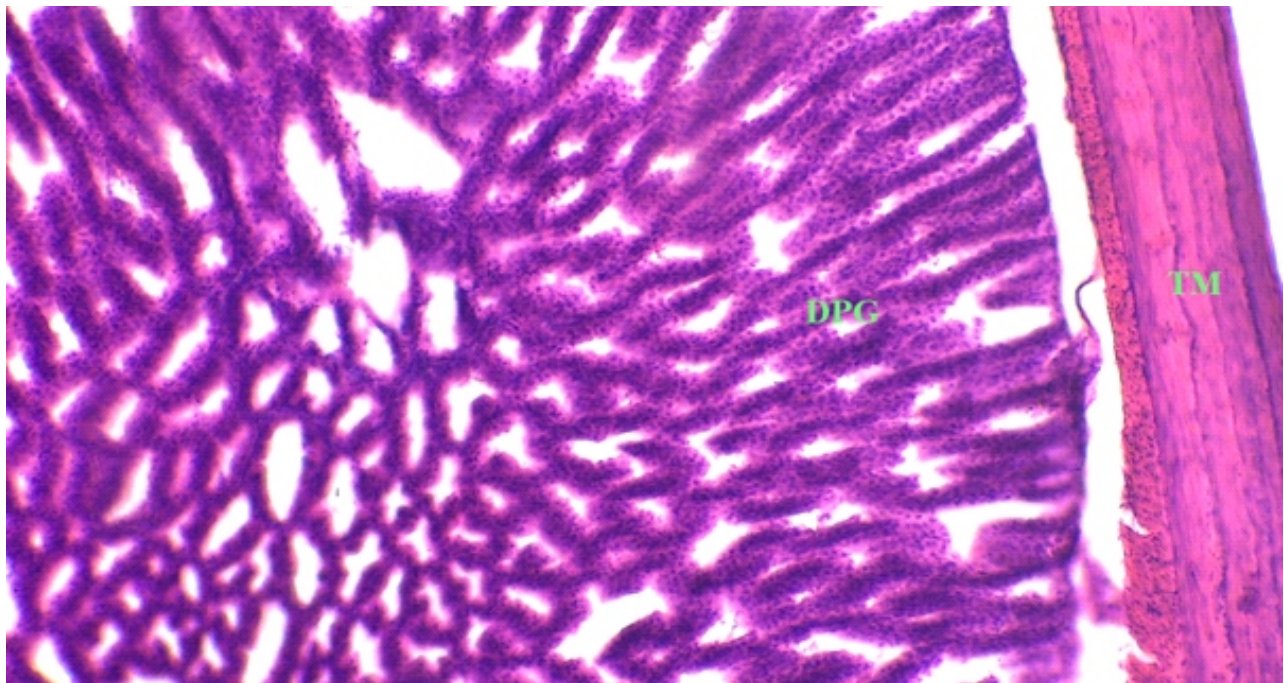
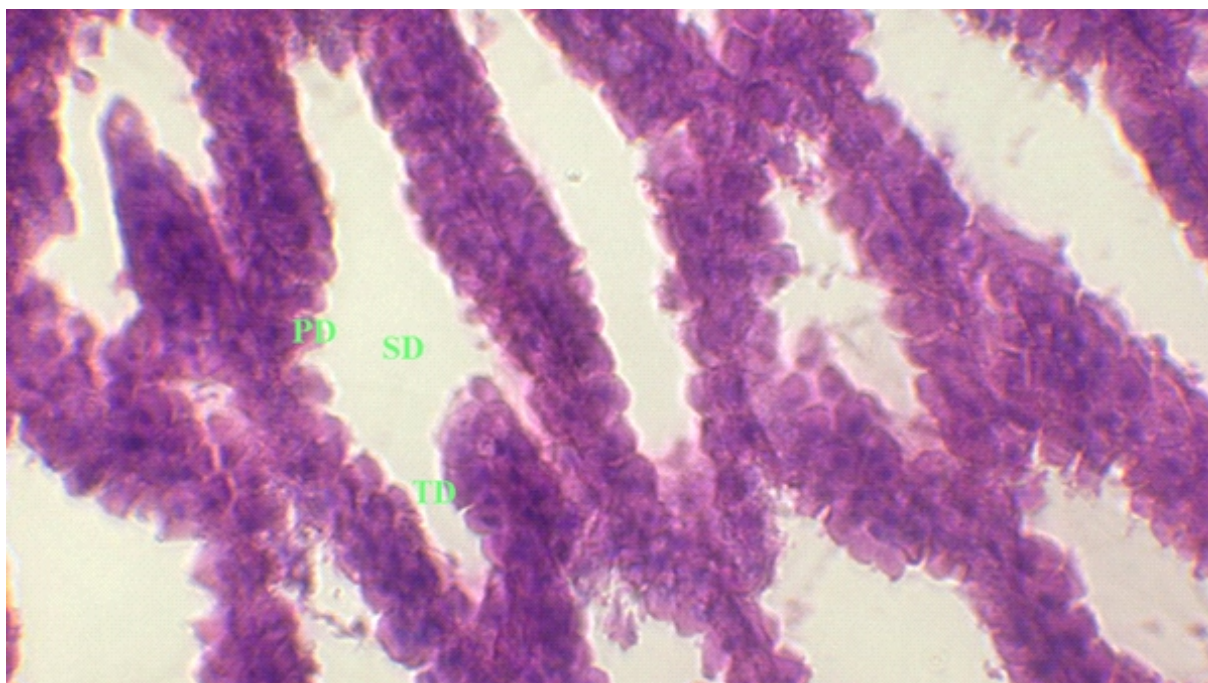


Fig.-6 : Photomicrograph of transverse section of gizzard of parent stock of Vanaraja showing PAS positive tubular glands in the region of laminae propria, PAS stain, X 400.

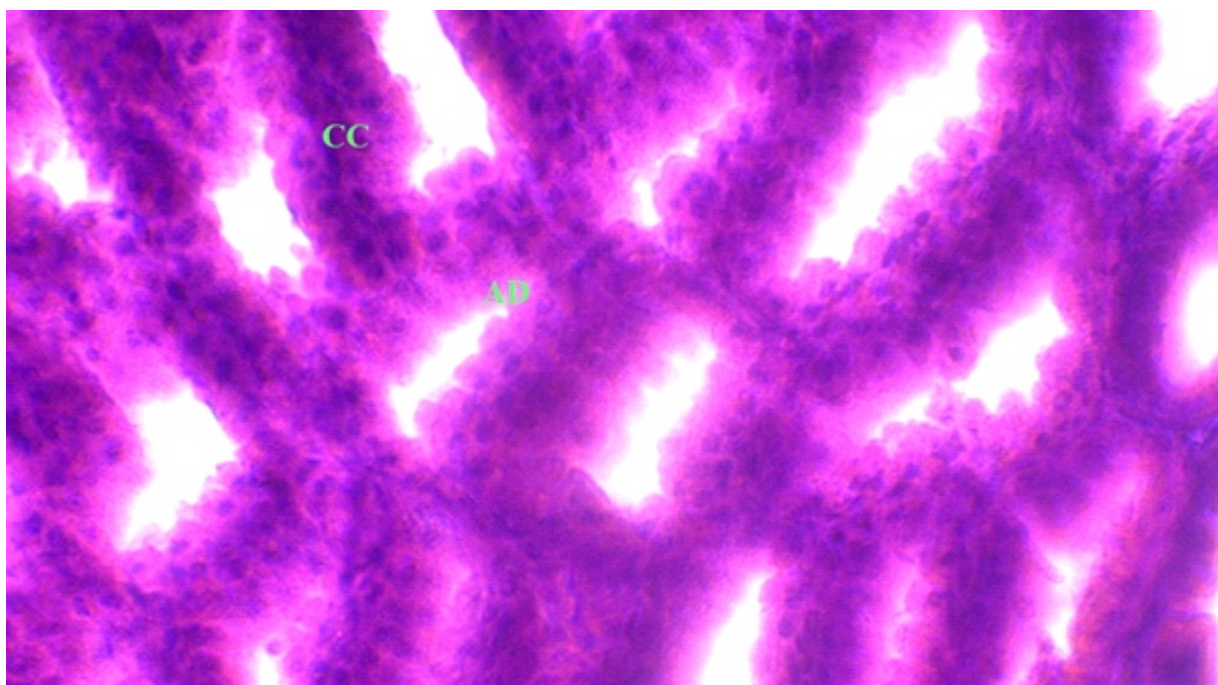
glands, within the deep glandular cells, within the cells lining the surface and crypts and also within the submucosa and between the smooth muscle bundles of tunica muscularis (Fig.-5&6.). The observations were in accordance to the findings made by (17) in the ventriculus of the black-winged kite (*Elanus caeruleus*) and (9) in the Guinea fowl (*Numida meleagris*). The positive colored

cuticle was recorded currently which was also observed by (18) in Quail.

Tunica submucosa consisted of connective tissue formed mainly from collagen fibers. The tunica muscularis was very thick formed from parallel bundles of smooth muscle fibers and were separated from each other by thin layer of collagen fibers. Well-developed blood vessels



**Fig.-7 :** Photomicrograph of transverse section of gizzard of parent stock of Vanaraja showing collagen fibers (CF) in the region of laminae propria, tunica muscularis and tunica serosa. Masson Trichome stain, X100.



**Fig.-8 :** Photomicrograph of transverse section of proventriculus of parent stock of Vanaraja showing collagen fibers (CF) in the region of laminae propria, tunica muscularis and tunica serosa and koilin layer (K). Masson Trichome stain, X100.

were observed within tunica muscosa. The tunica muscularis consisted of two muscular layers: inner circular layer and outer longitudinal layer of muscular fibers. This result was agreed with (19) in chickens, (20) in frugivorous, carnivorous and omnivorous species of birds, (17) in Coot bird. The present observation was in

disagreement with (21) who mentioned that in addition to these layers, oblique. muscle fibers formed the most internal layer of the tunica muscularis in the ventriculus of red jungle fowl. Tunica serosa was formed from connective tissue covered with mesothelium (fig.-7&8.). Tunica serosa consisted of loose connective tissue lined

by mesothelium, blood vessels and nerve elements as mentioned by (11).

## References

- Nath B.G., Pathak P.K. and Mohanty A.K. (2012). Constraints Analysis of Poultry Production at Dzongu Area of North Sikkim in India. *Indian J. Appl. Sci.*, 2: 397-401.
- Rupam Sinha, Meena Mrigesh, Ishwar Singh, Balwinder Singh and Niddhi Arora (2018). Sequential histomorphological and micrometrical studies on proventriculus of post hatch Uttara fowl. *J. Exp. Zool. India*, 21(1): 473-478.
- Luna LG. (1968). Manual of histologic staining methods of the armed forces institute of pathology. 3<sup>rd</sup> Edn. New York, McGraw-Hill.
- Abumandour M.M.A. (2014). Histomorphological studies on the stomach of Eurasian hobby (*Falconinae: Falco subbuteo*, Linnaeus 1758) and its relation with its feeding habits. *Life Sci. J.*, 11: 809-819.
- Zhu L., Wang J.J., Shi X.D., Hu J. and Chen J.G. (2013). Histological observation of the Stomach of the Yellow-billed Grosbeak. *Int. J. Morphol.*, 31(2): 512-515.
- Hassan S.A. and Moussa E.A. (2012). Gross and microscopic studies on the stomach of domestic duck (*Anas platyrhynchos*) and domestic pigeon (*Columbalivia domestica*). *J. Vet. Anat.*, 5: 105-127.
- Liman N., Alan E. and Bayram G.K., (2010). The differences between the localizations of Muc1, Muc5ac, Muc6 and Osteopontin on quail proventriculus and gizzard may be a reflection of functional differences of stomach parts. *J. Anat.*, 40: 57-66.
- Ogunkova Y.O. and Cook R.D. (2009). Histomorphology of the proventriculus of three species of Australian passerines: *Lichmera indistincta*, *Zosterops lateralis* and *Poephila guttata*. *Anat. Histol. Embryol.*, 38: 246-253.
- Selvan P.S., S. Ushakumary and G. Ramesh (2008). Studies on the histochemistry of the proventriculus and gizzard of post-hatch guinea fowl (*Numida meleagris*). *Int. J. Poult. Sci.*, 7: 1112-1116.
- Ahmed Y.A.E.G., G. Kmel and A.A.E.M. Ahmad (2011). Histomorphological studies on the stomach of the Japanese quail. *Asian J. Poult. Sci.*, 5: 56-67.
- Catroxo M.H.B., M.A.I. Lima and C.E.M.P.D.M. Cappellaro (1997). Histological aspects of the stomach (Proventriculus and gizzard) of the red-capped cardinal (*Paroaria gularis gularis*).
- Al-Saffar, Eyhab R.M. and Al-Samawy (2015). Histomorphological and histochemical study of stomach of domestic pigeon (*Columba livia domestica*). *The Iraqi J. Vet. Med.*, 40: 89-96.
- Batah A.L., Selman H.A. and Saddam M. (2012). Histological study of proventriculus and gizzard of Coot Bird (*Fulica atra*). *Diyala Agriculture Science Journal* 4(1): 9-16.
- Rocha D.O.S. and De Lima M.A.I. (1998). Histological aspects of the stomach of burrowing Owl (*Speotyto cunicularia*, Molina, 1782). *Rev. Chil. Anat.*, 16(2): 191-197.
- Akaster A.R. (1986). Structure of the glandular layer and koilin membrane in the gizzard of the adult domestic fowl (*Gallus gallus domesticus*). *J. Anat.*, 147: 1-25.
- Banks W.J. (1993). *Applied veterinary histology*. 3rd Edition, Mosbyyear Book Co., U.S.A. pp. 356-360.
- Hamdi H., A.W. El-Ghareeb, M. Zaher and F. Abu Amod (2013). Anatomical, histological and histochemical adaptations of the avian alimentary canal to their food habits: II-*Elanus caeruleus*. *Int. J. Scient. Eng. Res.*, 4: 1355-1364.
- Zaher M., A.W. EL-Ghareeb, H. Hamdi and F.A. Amod (2012). Anatomical, histological and histochemical adaptations of the avian alimentary canal to their food habits: I-*Coturnix coturnix*. *Life Sci. J.*, 9: 253-275.
- Hodges R.D. (1974). The Histology of the Fowl.: *Academic Press*, pp. 35-88.
- Jain D.K. (1976). Histomorphology and proteolytic activity in the gastric apparatus of frugivorous, carnivorous and omnivorous species of birds. *Acta Biol. Acad. Sci. Hung.*, 27: 135-45.
- Kadhim K.K., A.B.Z. Zuki, M.M. Noordin, S.M.A. Babjee and M. Zamri-Saad (2011). Activities of amylase, trypsin and chymotrypsin of pancreas and small intestinal contents in the red jungle fowl and broiler breed. *Afr. J. Biotechnol.*, 10: 108-115.